



# VARIATION IN ORIGIN AND COURSE OF BRACHIAL ARTERY AMONG BLACK AFRICAN POPULATION: CADAVERIC STUDY IN WESTERN KENYA

Oyale Warren Ayonga<sup>1</sup>, Willis Oyieko<sup>1</sup>, Paul Kosiyo<sup>2</sup> Domic Marera<sup>1</sup>

<sup>1</sup>Department of Human Anatomy, School of Medicine, Maseno University, Kisumu, Kenya.

<sup>2</sup>Department of Medical Laboratory Science, School of Medicine, Maseno University, Kisumu, Kenya.

Corresponding Author: Dr. Oyale Warren Ayonga, Email: [warrenwary@gmail.com](mailto:warrenwary@gmail.com)

ORCID ID: 0000-0003-0970-6985

## ABSTRACT

**Background:** Brachial artery (BA) is the main arterial supply to upper limb, it's a direct continuation of axillary artery at the lower border of teres major and gives off profunda brachii which is the largest branch, superior ulnar collateral artery, inferior ulnar collateral artery, nutrient artery and muscular branches. BA presents with a lot of anatomical variants as reported by several authors though there is paucity of data on this variant anatomy among black African population. The current study evaluated variation in origin and course of brachial artery among black African population. **Methodology:** This descriptive cross-sectional study was carried out in three universities, in western Kenya due to their well-established functional Human Anatomy laboratory used by medical students. The study involved 77 cadavers (n=154 upper limbs) of 39 males and 38 females obtained through stratified sampling technique. Data collected was collated in excel sheet and analyzed using statistical package of social sciences (SPSS) version 26.0. Descriptive statistics was used to assess frequency distribution of variant origin while Chi square was used to determine difference in proportion of normal origin and cumulative variation of BA regards with to laterality of the upper limb. Brachium region was exposed to access the brachial artery where origin and its course was assessed. **Results:** Out of 154 upper limbs examined 3.8% had variation in origin of brachial artery, 2.6% showed superficial origin and superficial course of brachial artery terminating into its terminal branches. However, this variation was not statistically significant. **Conclusion:** There were variations in origin of brachial artery among black African population, these variations were more on the right upper limb than the left upper limb, though not statistically significant but clinically significant, hence health care professionals, anatomists and medical students should be made aware of such variants when performing invasive procedures to avoid complications, misdiagnosis and any medical errors that might occur as a result of such variants. Understanding existence of such variants leads to good patient care and outcome after surgical and radiological procedures thus reducing misdiagnosis and mismanagement of patients. **Keywords:** Brachial artery; Origin; superficial brachial artery.

**DOI:** <https://dx.doi.org/10.4314/aja.v13i1.13>

## INTRODUCTION

Arterial variations in the upper limb were first noted by Von Haller in 1813 (Bidarkotimath et al., 2012). *Quains (1844)* was believed to be the first person to provide sufficient data for useful statistical evaluation regarding the brachial artery? (Tsoucalas et al., 2020). The brachial artery (BA) is the major arterial supply of the upper limb, it commences at the inferior border of teres major as a direct continuation of the 3<sup>rd</sup> part of axillary artery and courses to the arm anterior to triceps

and brachialis muscle, it terminates at the neck of the radius by dividing to radial and ulnar arteries (Tsoucalas et al., 2020).

In the arm, it is superficial in its course and gives off the following branches; profunda brachii which is the largest branch and supplies triceps brachii, superior and inferior ulnar collateral (SUC&IUC) arteries, muscular branches to supply muscles of anterior compartment of the arm i.e., biceps brachii, coracobrachialis and brachialis, nutrient

artery to the humerus, and terminates into the ulnar and radial arteries. (George et al., 2019; Gupta et al., 2012).

The BA is of clinical importance to health care professionals for its use clinically such as brachial pulse identification, blood pressure monitoring, arteriography, percutaneous arterial catheterization, and arteriovenous fistula (AVF) for dialysis patients and various radiological interventions. Variations in the morphology and branching pattern in the BA and its course may lead to misdiagnosis i.e., pulse, blood pressure monitoring and in interventional radiological procedures hence there is need to evaluate such variations.

Based on several hypotheses, there are several variations in the origin of the BA. For example; the artery can divide into two trunks proximally, which then reunite, it can course superficially, originating from third part of axillary artery or main trunk of brachial artery, in front rather than behind the median nerve. It may have a high division into its terminal branches, most commonly seen as radial artery arises first (high origin of radial artery-brachioradial artery) while ulnar artery and common interosseous continuous as a common trunk (Kaur et al., 2017)

A study conducted on 70 cadavers, where 140 upper limb specimens were dissected, found out that there was an accessory

brachial artery arising from the axillary artery along with the main brachial artery in (14.3%) of specimens, it had its course above median nerve. Accessory brachial artery (ABA) did not have any branches and profunda brachii was seen originating from of axillary artery in 6 cadavers (8.57%) (Chakravarthi et al., 2014). A study conducted by Pulei et al., (2012), on 162 upper limb specimens found out that, 6.1% had superficial brachial artery. Such superficial origin and course of brachial artery is described in its relation to median nerve, as it courses superficial to median nerve (Prasada-Rao & Chaudhary, 2001).

Because of its clinical importance, knowledge on BA variation is important to health care professionals, specifically surgeons, and radiologists including anatomists as the brachial artery is used in various diagnostic procedures e.g., blood pressure monitoring, arteriovenous fistula for dialysis in patients with chronic kidney injury, interventional/surgical procedures of the upper arm to avoid complications such as Volkmann's ischemic contracture (Ayonga et al., 2023; Narayanan & Murugan, 2018). Due to inadequate data on variation of brachial artery and its branching pattern especially among black African the population, there is need to explore this specific research area. As such the current study therefore, evaluated the variation in origin and course of brachial artery in black African population.

## **MATERIALS AND METHODS**

### **Study site**

This study was carried out in three human anatomy laboratories in western Kenya namely Maseno, Masinde Muliro and Uzima universities used by undergraduate medical students during their routine dissection. Laboratories were identified purposively and conveniently based on of their functional human anatomy laboratories, as they had met commission of university education (CUE) standards for storage of human tissues in western Kenya.

### **Study design and sample size calculation**

The current study used a descriptive cross-sectional study design. Yamane taro formulae (1970) was used to calculate the sample size and 77 cadavers (n=154 upper limb) from a pull of 96 cadavers though Stratified sampling technique. To ensure uniformity in distribution of samples, sampling was done proportionately with the strata population by location, where the sample size per laboratory was further

calculated by dividing laboratory cadavers (*d*) by total location population (96), then multiplying by the desired sample size (77)  $n = (d \times 77 / 96)$ .

**Inclusion criteria:** Only cadavers with intact upper limbs were included in the study therefore, a total of 154 upper limb specimens of 77 cadavers, 39 males and 38 females were finally picked.

**Exclusion criteria:** Cadavers with deformities on the upper limbs were excluded from the study. Cadavers suggestive of being non-African in origin through physical examination were also excluded.

### Laboratory procedures

To expose the BA the following procedure were to be followed as per the Cunninghams dissection manual. Fascia underlying pectoralis minor muscle was cleaned and inferior part of the axillae opened up. Lateral part of pectoralis minor, short head of biceps and coracobrachialis were exposed and cleaned up. Lower part of the axillae was cleaned and pectoralis minor divided midway between its point of origin and insertion and reflected. The teres major muscle was identified and brachial artery located.

Skin and superficial fascia was reflected and deep fascia dissected longitudinally along middle of biceps brachii. Transverse incision was made at the level of epicondyles and each flap reflected.

### Origin of the brachial artery in the total upper limbs

In the current study, out of 154 upper limb specimens dissected, 50.6% (39) males and 49.4% (38) females, variations in origin of brachial artery were noted in 3.8% (6 upper limbs). Superficial brachial artery accounted for 2.6% (4 upper limbs). Superficial brachial

artery was seen coursing above median nerve and terminating at the neck of radius into its two terminal branches, ulnar and radial arteries. There was no presence of deep brachial artery, profunda brachii in 2 specimens originated from third part of axillary artery. (Table 1)

Origin of BA and its branches were located, the area was cleaned up and BA branches traced. In the cubital fossa, bicipital aponeurosis was dissected and terminal branches of BA (radial & ulnar arteries) were exposed and keenly observed. Origin of the BA and its branches were located, the area was cleaned up and BA branches traced. In the cubital fossa, bicipital aponeurosis was dissected and terminal branches of BA (radial & ulnar arteries) was exposed and keenly observed. The skin around the brachium was exposed and muscles identified. Brachial artery was identified, its origin and course noted.

### Data management and statistical analysis

Data collected was collated in excel sheet and analyzed using statistical package of social sciences (SPSS) version 26.0, photomicrographs were taken for any variation noted, descriptive statistics was used to assess frequency distribution while chi square test was used to test for significance of any variation and recorded in form of tables.

**Ethical consideration:** Ethical approval was sought from Maseno university ethical and research committee (MSU/DRPI/MUSERC/01140/22) and National commission of science technology and innovations (NACOSTI/P/23/22873).

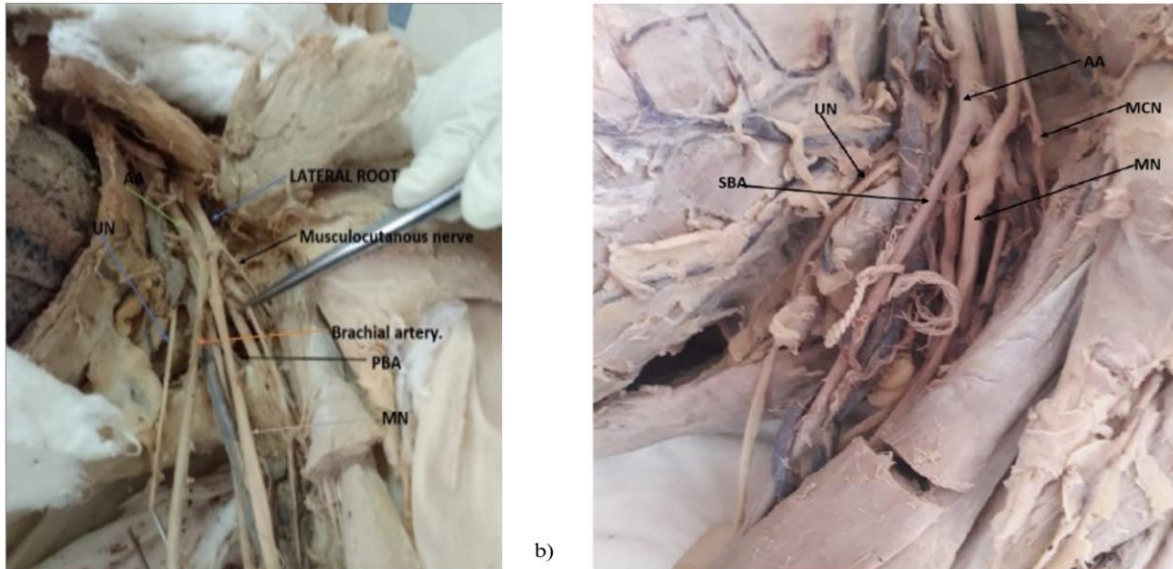
## RESULTS

artery was seen coursing above median nerve and terminating at the neck of radius into its two terminal branches, ulnar and radial arteries. There was no presence of deep brachial artery, profunda brachii in 2 specimens originated from third part of axillary artery. (Table 1)

**Table 1: Origin of the brachial artery in the total upper limbs (n=154)**

origin of the brachial artery	N	%	Valid Percent	Cumulative Percent
Brachial artery and profunda brachii originating from axillary artery	1	0.6	0.6	0.6
Normal	148	96.1	96.1	96.8
Normal origin. profunda brachii originating from 2nd part of axillary artery.	1	0.6	0.6	97.4
Superficial origin of brachial artery.	4	2.6	2.6	100.0
Total	154	100.0	100.0	

Cross tabulation in origin of BA and its variants in percentage and cumulative percentage



**Figure 1: a)** Variation in the origin of brachial artery; Origin of superficial brachial artery in relation to Median nerve (MN), Musculocutaneous nerve, Ulnar nerve (UN) and lateral root of brachial plexus. **b)** Origin variation in BA, superficial brachial artery seen originating from axillary artery. AA-Axillary artery; SBA-Superficial brachial artery; UN-Ulnar nerve; MCN-Musculocutaneous nerve; MN-Median nerve.

**Comparison between the normal origin and variations in the origin of brachial artery and laterality.**

Variant origin of brachial artery was more common in the right than on the left limb. There was no statistically significant difference variation in the left and right upper limb ( $p=0.320$  and  $p=0.157$ ) respectively in the origin of brachial artery relative to the normal branching pattern. Data shows degree of freedom and p values. Both limbs were categorized in left and right BA. Statistical significance was determined by chi-square ( $X^2$ ) analysis at  $p$  value  $<0.05$ .

**Table 2: comparison between the normal origin and variations in the origin of brachial artery and laterality.**

Pearson Chi-Square Tests		
		NORMAL.
ORIGIN LEFT.	Chi-square	0.987
	df	1
	p value	0.320
ORIGIN RIGHT.	Chi-square	5.210
	df	3
	p value	0.157

**Comparison between origin of brachial artery and sex.**

The other groups are defined based on variations in the origin or termination of the brachial artery. The results show that in the group with a superficial origin of the brachial artery, there were no variations noted in

females, but one male had this variation, representing 1.3% left and 3.9% right of males. The COR and AOR for this group were 1.21 (95% CI: 0.67-2.20) and 1.15 (95% CI:

0.60-2.20), respectively, and the p-value was not statistically significant ( $p=0.654$ ) and ( $p=0.654$ ) (Table.3)

**Table 3: Relation between the origin of the brachial artery and sex**

OTBA		Total		Gender				COR (95% CI)	AOR (95% CI)	p-value
				Female		Male				
		n	%	n	%	n	%			
OL	Normal	76	98.7%	38	49.4%	38	49.4%	Ref.	Ref.	
	SOBA	1	1.3%	0	0.0%	1	1.3%	1.21 (0.67-2.20)	1.15 (0.60-2.20)	0.654
OR	Normal	72	93.5%	0	0.0%	1	1.3%	Ref.	Ref.	
	BAPOA	1	1.3%	0	0.0%	1	1.3%	0.92 (0.26-3.27)	0.97 (0.26-3.61)	0.958
	NOPBOA	1	1.3%	0	49.4%	1	44.2%	0.92 (0.26-3.27)	0.88 (0.23-3.34)	0.851
	<b>SOBA.</b>	<b>3</b>	<b>3.9%</b>	<b>0</b>	<b>0.0%</b>	<b>3</b>	<b>3.9%</b>	<b>1.78 (0.57-5.55)</b>	<b>1.62 (0.50-5.24)</b>	<b>0.406</b>

Note: COR = crude odds ratio, AOR = adjusted odds ratio, CI = confidence interval. P-value represents the statistical significance of the comparison between the origin of the brachial artery and sex after adjusting for the origin of the other limb. **OTBA**-Origin and termination of brachial artery **OL**-Origin on the left; **OR**-Origin on the right; **SOBA**-Superficial origin of brachial artery; **BAPOA**-Brachial artery and profunda brachii originating from axillary artery; **NOPBOA**-Normal origin. profunda brachii originating from 2nd part of axillary artery; **SOBA**; Superficial origin of brachial artery.

## DISCUSSION

Normally, brachial artery originates as a continuation of third part of axillary artery at the lower border of teres major and is located below the median nerve in its course. In the current study, out of the total 154 upper limb specimens, 3.8% (6/154) had a variant origin. These variations were lower than a study by (Shivanal, 2013) who reported 16% variant origin of brachial artery. This lower proportion in variation may be attributed to geographical origin, embryological development, gender and race. Sharma et al., (2009) observed origin of superficial brachial artery from third part of axillary artery which corroborated with the findings of the current study.

Superficial origin of brachial artery was reported as the most common variation at 2.6% in the current study, this could be attributed to race, geographical location, gender and embryological origin, which have previously been shown to cause some of the upper limb arterial variants (Klimek-Piotrowska et al., 2013). Even though variant origin and course of superficial brachial artery in the current study were much lower, a study on Korean cadavers by (Yang et al.,

2008) reported 12.2% (37) upper limb specimens had superficial brachial artery as the most common variant in origin, which is further reinforced by our findings. Unlike the current study, a study by (Chakravarthi et al., 2014) recorded accessory brachial artery as the most common variant accounting for 11.43% (8) upper limbs specimens. This disparity from our finding could be due to number of specimens used in the study, race, gender evolutionary changes and geographical location. In a study conducted among Caucasians in South Africa, three cases had superficial origin of brachial artery unilaterally, of the three, two cases were seen on the right limb while one case was seen on the left (Nkomozepi et al., 2017). These arterial patterns can be explained by existence during developmental process of arteries of the arm of a superficial brachial artery and an anastomotic branch between the superficial brachial artery and the brachial artery (Nakatani et al., 1996; Oyale Warren Ayonga et al., 2023). Such superficial course of brachial artery serves as a route for catheter during the radial approach to coronary procedures for catheterization

(Chakravarthi et al., 2014). Superficial brachial artery may be prone to injuries because of its superficial course and may be affected or become ischemic during normal clinical procedures administering intravenous injections in outpatient/ inpatient set up. There was no statistically significant difference in the normal origin of brachial artery when compared to variant origin, this shows that these variations are not significant and occurs on individual basis. This finding is reinforced by that of Yang et al.,(2008) who reported no statistically significant difference between normal and variant origin of superficial brachial artery. Normally, the left and right brachial artery have similar origin, course, distribution as reported in standard human anatomy text books (Standring, 2021), however, few variations in laterality has been reported previously (Lalit & Piplani, 2021; Patnaik et al., 2002). In the current study, the commonest variation in terms of laterality was in superficial origin of brachial artery on the right side, with an incidence of 1.3%. This finding was similar to a study conducted on 56 upper limb specimens in India (17) which reported a 1.78% variation in origin of brachial artery occurring more on the right than the left upper limb. In another study in Chennai, Madras medical college in Asia (Gohila, 2017) on 25 adult human cadavers of 50 upper limb specimens, 4% (2/154) incidence of superficial brachial artery in the right upper limb was reported which concurs with our finding in the current study. Therefore, it is apparent that more variations in the origin of brachial artery occur on the right upper limb than the left side. This could be attributable to frequent activity since majority use their right upper limb more often than the left upper limb however, this needs more exploration with respect to age of the cadaver. Though, there was no reported statistically significant variation between laterality and variant origin of

brachial artery in the current study( $p=0.406$ ) and the literature reviewed.

### **Study limitations.**

Long dissecting hours and few female cadavers. Furthermore the study design used in the current limited the interpretation of causality of these variations.

### **Conclusions**

There were considerable variations in origin and termination of brachial artery among the study population, however, the variation from the normal morphology was not statistically significant.

There was no significant variation in origin between sexes however, males appeared to have more variations in origin, in addition, variations in origin were more common on the right side than the left side.

### **Recommendations**

Knowledge about variations in superficial origin of brachial artery is important to Anatomist, surgeons, radiologists, cardiothoracic and vascular surgeons, due to variant patterns observed thus each individual should be treated as a special case to avert complications and mismanagement of patients. Further population specific studies should be carried out especially on evolutionary and racial differences among Caucasians, blacks and Asians to guide in the developmental variations.

### **Source of funding**

This study did not receive any funding from any organization.

### **Conflict of interest**

The authors of this study declare no conflict of interest.

### **Acknowledgement**

We would like to acknowledge the technical staff the department of Human anatomy Maseno, Uzima and Masinde Muliro universities for their support and access to the research materials.

## REFERENCES

1. Ayonga, O. W., Kosiyo, P., & Oyioko, W. (2023). Variation in Termination of Brachial Artery Among Black African Population. *Journal of Natural Sciences Research*, 14(12), 11.
2. Bidarkotimath, S., Avadhani, R., & Kumar, A. (2012). An anatomical study of primary pattern of arteries of upper limb with relevance to their variations. *Journal of Health and Allied Sciences NU*, 2(01), 08–14.
3. Chakravarthi, K. K., Siddaraju, K. S., Venumadhav, N., Sharma, A., & Kumar, N. (2014). Anatomical variations of brachial artery-its morphology, embryogenesis and clinical implications. *Journal of Clinical and Diagnostic Research: JCDR*, 8(12), AC17.
4. George, J. R., Francis, J., Samuel, J. E., & Francis, T. (2019). Morphology and variations of brachial artery in cadavers. *Int J Anat Res*, 7(2.3), 6680–6684.
5. Gohila, G. (2017). *A Study of brachial artery, its branching pattern and variations with clinical applications* [PhD Thesis]. Madras Medical College, Chennai.
6. Gupta, J., Jain, R., & Patil, M. (2012). A study of brachial artery with high up division and its clinical significance. *Int J Bioassays*, 1, 116–118.
7. Kaur, A., Sharma, A., & Sharma, M. (2017). Variation in branching pattern of brachial artery. *International Journal of Scientific Study*, 5(1), 213–217.
8. Klimek-Piotrowska, W., Pacholczak, R., & Walocha, J. (2013). Multiple variations of the arterial pattern in upper extremities: A case report and embryological pathogenesis. *Clinical Anatomy*, 26(8), 1031–1035. <https://doi.org/10.1002/ca.22171>
9. Lalit, M., & Piplani, S. (2021). A cadaveric study of brachial artery and its variations with its ontogenic basis: An anatomical perspective. *Int J Anat Res*, 9(1.1), 7844–7850.
10. Nakatani, T., Tanaka, S., & Mizukami, S. (1996). Superficial brachial arteries observed in bilateral arms. *Kaibogaku Zasshi. Journal of Anatomy*, 71(4), 308–312.
11. Narayanan, S., & Murugan, S. (2018). Bifurcation of brachial artery into a common radial–interosseous trunk and superficial ulnar artery: A rare variation. *Anatomical Science International*, 93, 400–403.
12. Nkomozepi, P., Xhakaza, N., & Swanepoel, E. (2017). Superficial brachial artery: A possible cause for idiopathic median nerve entrapment neuropathy. *Folia Morphologica*, 76(3), Article 3. <https://doi.org/10.5603/FM.a2017.0013>
13. Oyale Warren Ayonga, Oyioko, W., Kosiyo, P., Dominic Marera, & Omuga Phillip Charles. (2023). *Variation in Branching Pattern and Length of Brachial Artery among Black African Population*. <https://doi.org/10.5281/ZENODO.8141808>
14. Patnaik, V. V. G., Kalsey, G., & Singla, R. K. (2002). Branching pattern of brachial artery-A morphological study. *J Anat Soc India*, 51(2), 176e86.
15. Prasada-Rao, P. V. V., & Chaudhary, S. C. (2001). *Superficial brachial artery terminating as radial and superficial ulnar arteries: A case report*.
16. Pulei, A., Obimbo, M., Ongeti, K., Kitunguu, P., Inyimili, M., & Ogeng’o, J. (2012). Surgical significance of brachial arterial variants in a Kenyan population. *Annals of African Surgery*, 9.
17. Sharma, T., Singla, R. K., & Sachdeva, K. (2009). Bilateral superficial brachial artery. *Kathmandu University Medical Journal*, 7(4), 426–428.
18. Shivanal, U. (2013). *A study of variations in brachial artery and its branching pattern* [PhD Thesis]. Rajiv Gandhi University of Health Sciences (India).
19. Standring, S. (2021). *Gray’s anatomy e-book: The anatomical basis of clinical practice*. Elsevier Health Sciences.
20. Tsoucalas, G., Eleftheriou, A., & Panagouli, E. (2020). High bifurcation of the brachial artery: An embryological overview. *Cureus*, 12(2).

21. Yang, H.-J., Gil, Y.-C., Jung, W.-S., & Lee, H.-Y. (2008). Variations of the superficial brachial artery in Korean cadavers. *Journal of Korean Medical Science*, 23(5), 884–887.